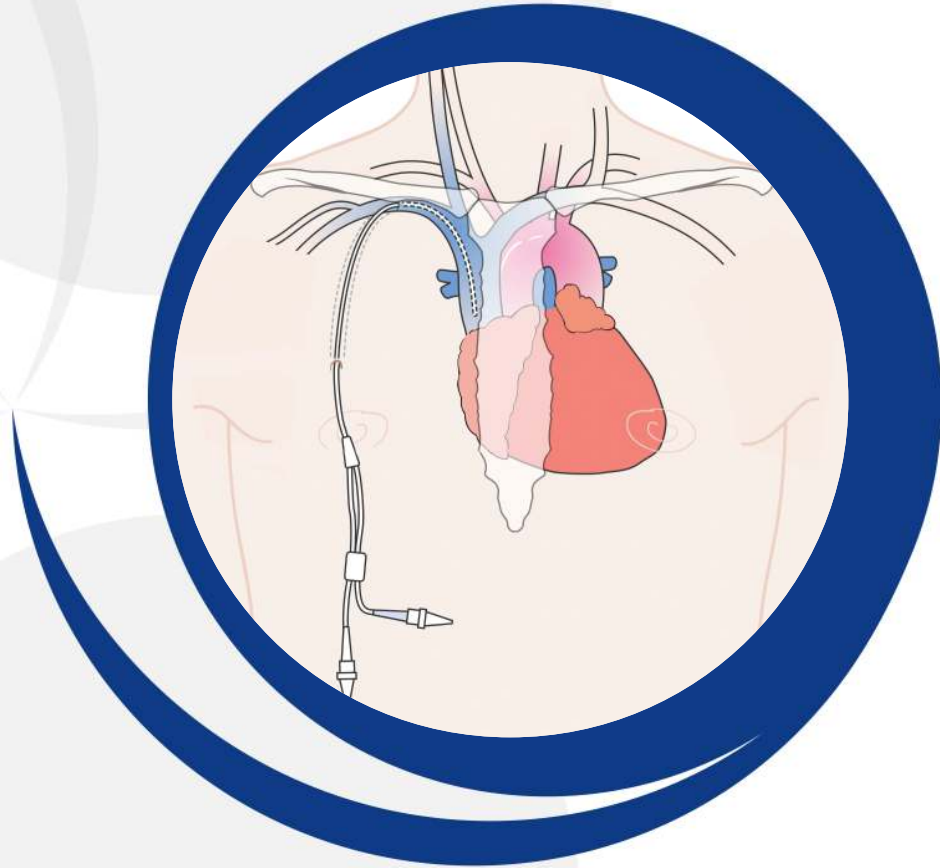

## **Tunnelled Central Venous Catheters**

# TCVC

What is it?

AKA:

- Tunnelled cuffed catheter
- Hickman line
- Hickman® type catheter
- Broviac catheter
- Tunnelled central venous catheter
- Tunnelled Central venous access device

Vascular Access Devices with a tip that terminates in one of the large central veins (Superior Vena Cava or Upper Right Atrium).

# Vygon Lifecath TCVC

- Made from radiopaque silicone
- Single, double or triple lumen which allow simultaneous delivery of multiple medications or fluids
- They offer long-term venous access for therapies including parenteral nutrition, medication delivery, antibiotics and chemotherapy.

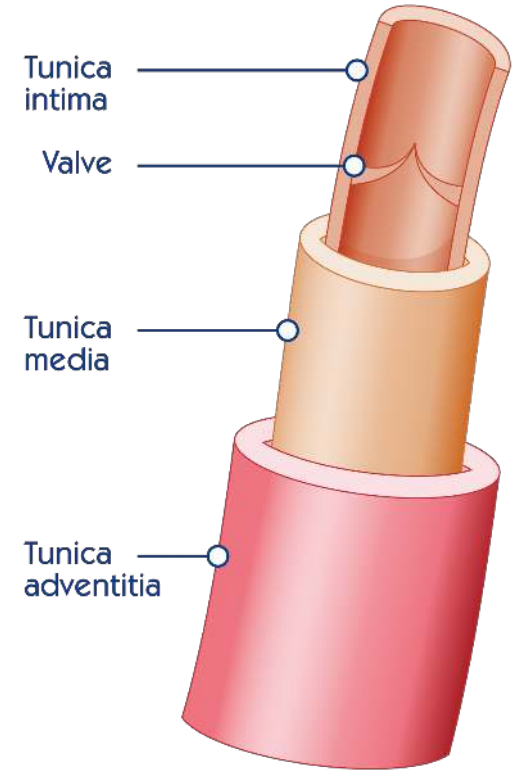
# Insertion techniques

- Normally inserted via the neck or chest veins (internal jugular or subclavian vein)
- The catheter typically exits at the upper chest
- The catheter travels through a short (8-15cm) subcutaneous tract before entering the access vein
- One feature of these devices is the Dacron® cuff. The cuff is important as it aids catheter stabilisation and helps to prevent infection.

# TCVC

## Advantages and indications

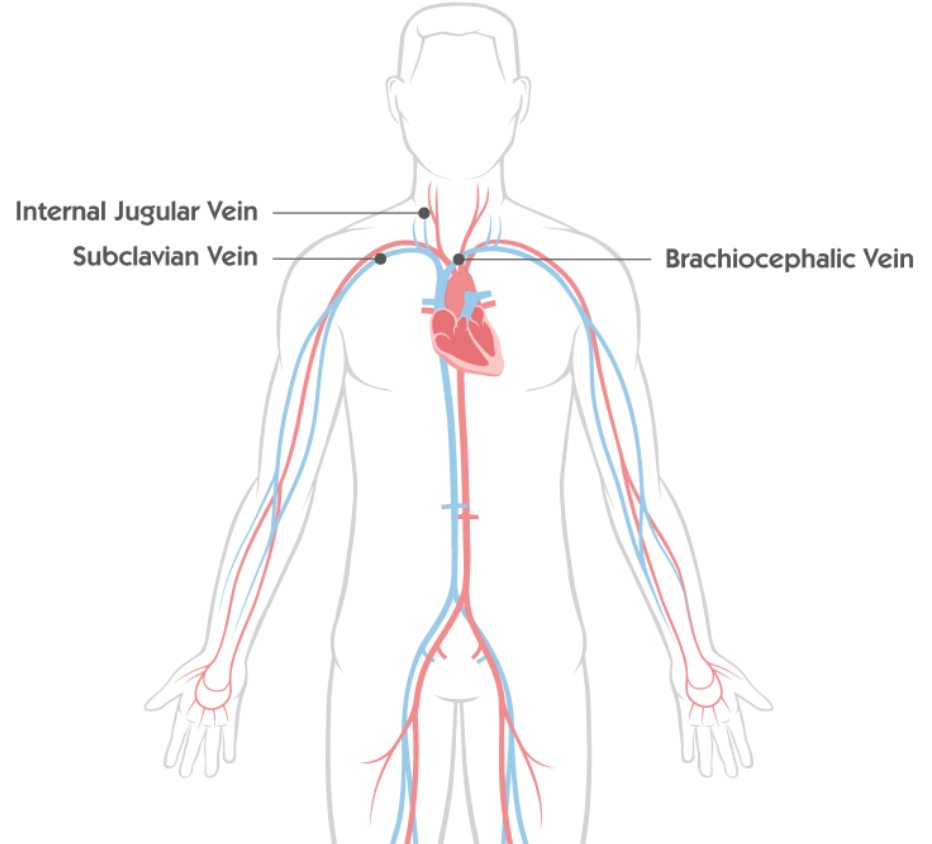
- Provides long term venous access
- Indications:
  - Prolonged treatments
  - Chemotherapy
  - Antibiotic therapy
  - TPN
  - Renal dialysis
- Ability to obtain and administer bloods
- Prevents irritation or damage to smaller veins
- Inability to access arm veins
- Outpatients or inpatients use
- Think about the patient preference.



# Neck and chest veins

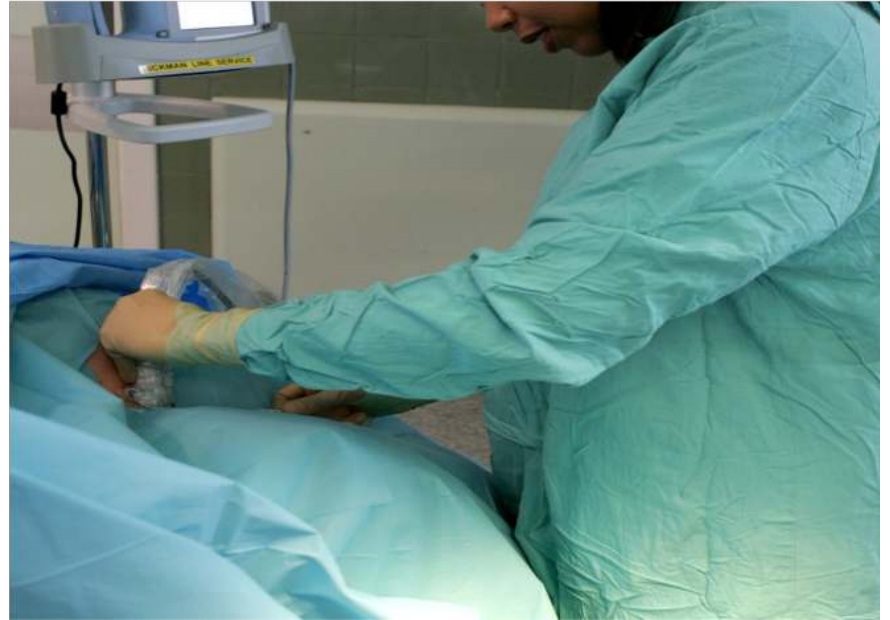The typical venous **access point** for TCVCs and TIVADs are:

- Internal Jugular Vein (IJ)
- Subclavian Vein
- Brachiocephalic vein  
(left and right innominate veins)



# Venous access

- Use ultrasound to assess the intended access vein
- Use the ReCeVA protocol
- Check for size and patency.



# TCVC

## Insertion

- **Operators**
  - Surgeons
  - Anaesthetists
  - Radiologists
  - Nurses
  - Radiographers
- **Imaging modalities**
  - Ultrasound guided
  - Fluoroscopy
- **Area**
  - Theatres
  - Radiology suite
  - IR suite
  - Anaesthetic room
  - Treatment room
  - Bedside

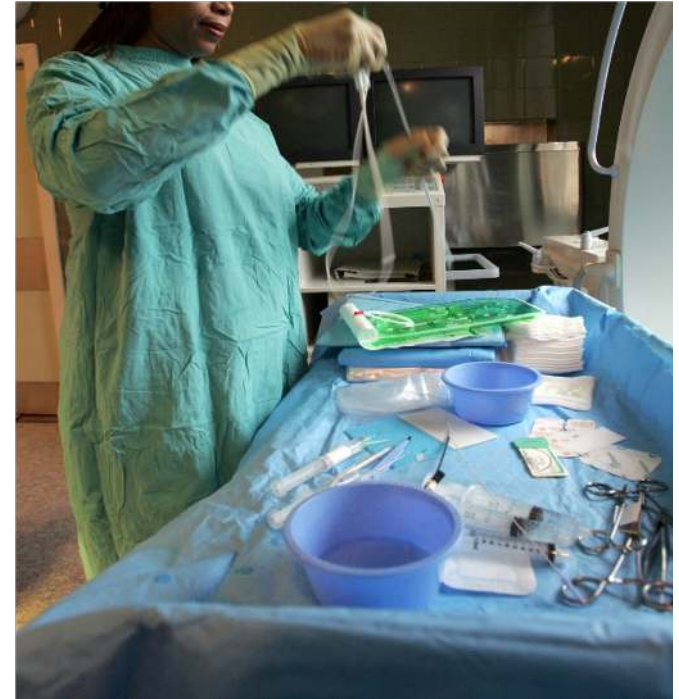


# TCVC

## Insertion

- The insertion of a TCVC is a surgical ANTT
- Hands should be washed using a surgical scrub technique
- The operator performing the procedure will perform a full surgical scrub and will wear a scrub suit, theatre gown and sterile gloves, hat and mask (Loveday 2014)
- Consider the use of standard insertion packs.

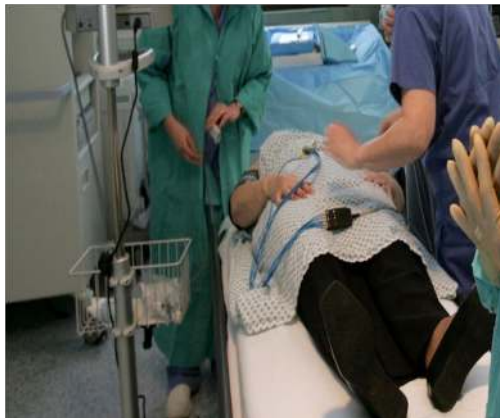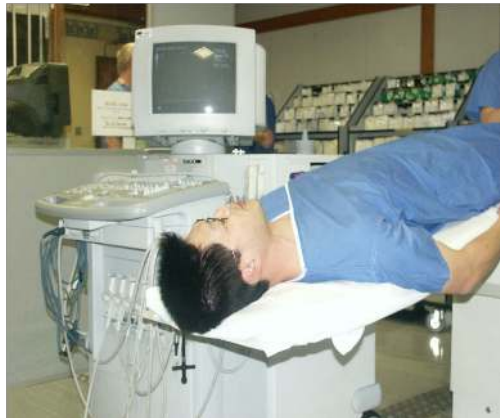Ref: Loveday HP, Wilson JA, Pratt RJ et al (2014) Epic3: national evidence-based guidelines for preventing healthcare-associated infections in NHS hospitals in England. *J Hosp Infect* **86**(Suppl 1): S1-70.



# Patient

## Positioning

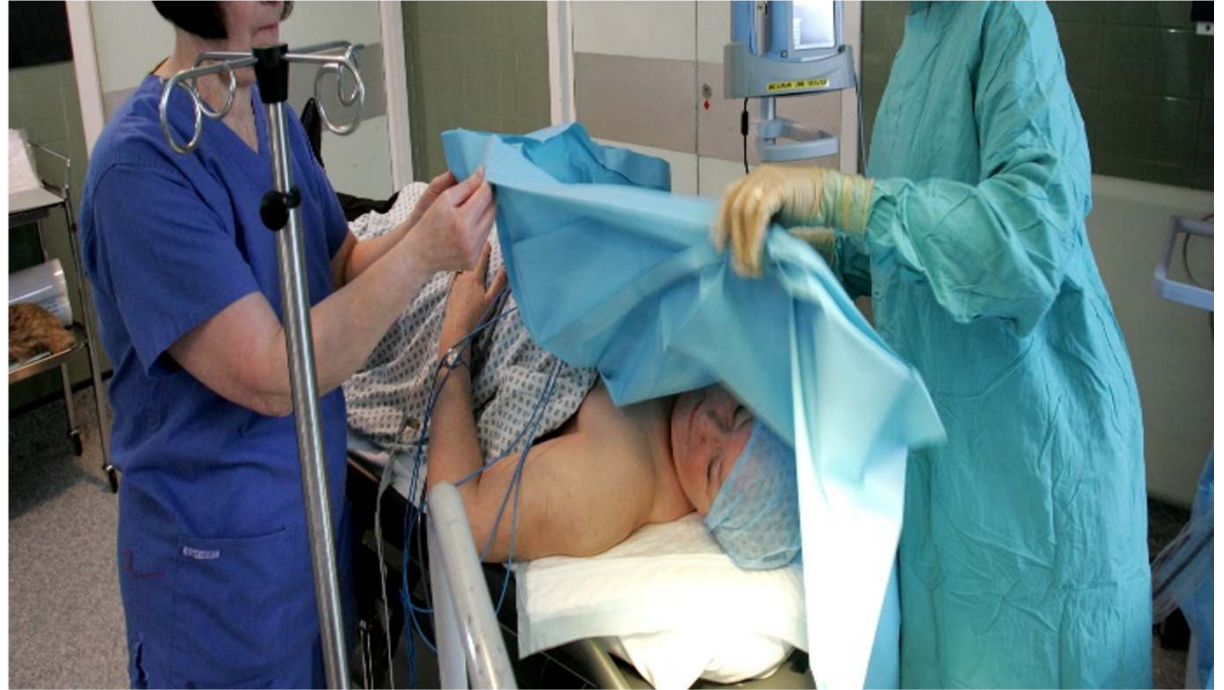- The patient should lay flat on a trolley or table
- The head should be tilted down about 30° (Trendelenburg position). This will allow good vein filling and also help prevent air embolism
- All patients should routinely have blood pressure, pulse, oxygen saturations and ECG recorded during the procedure.



# Patient

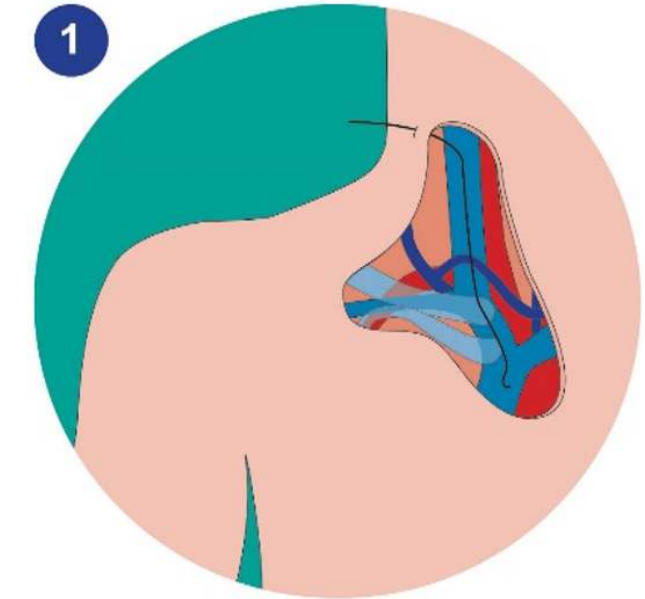
## Preparation

- Clean skin using chlorhexidine 2% in 70% alcohol
- Fully drape
- Fenestration
- Exit site.



# Ultrasound guidance

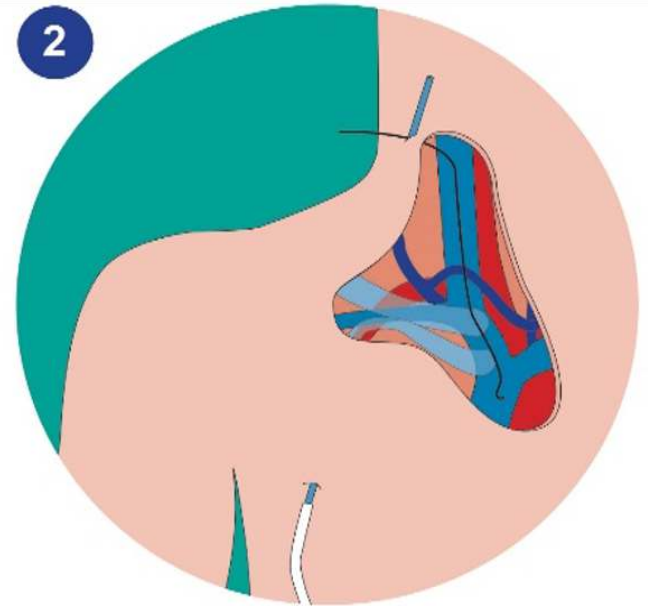
- Prepare probe
- Administer local anaesthesia
- Access vein
- Insert guidewire.



Puncture to jugular vein using 19g needle, wire introduced.

# Tunnel creation

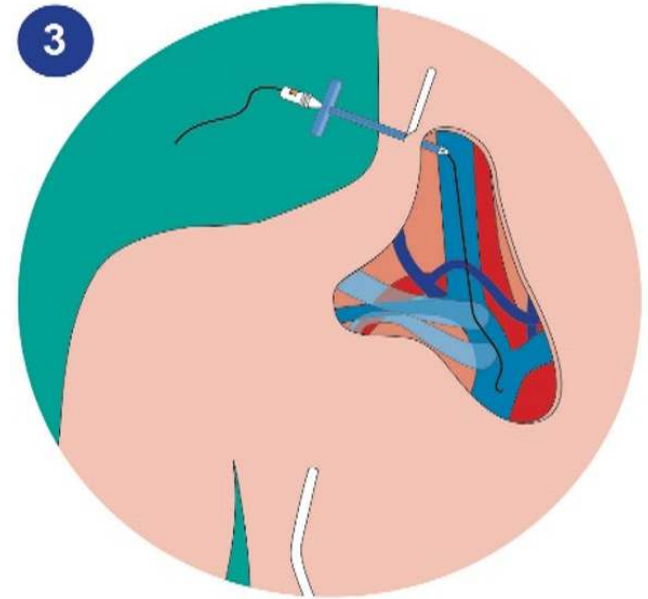
- Anaesthetise the tunnel site
- Insert the metal tunnel under the subcutaneous tissue and bring it out beside the guidewire
- Measure down the chest to approximately 13cm
- Cut the tunneller off.



Tunnel fashioned back to point of entry.

# Peel away sheath introduction

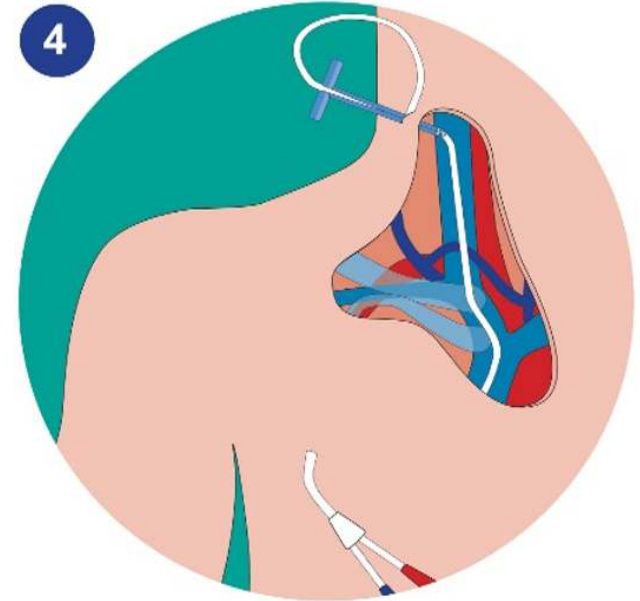
- The peel away sheath is inserted over the wire
- The wire is removed along with the inner dilator
- Immediately place a finger over the open-ended sheath (to prevent air embolism)
- At this point the patient can also be instructed to hold their breath or to perform the Valsalva maneuver.



Peel away sheath advanced over wire.

# Peel away sheath

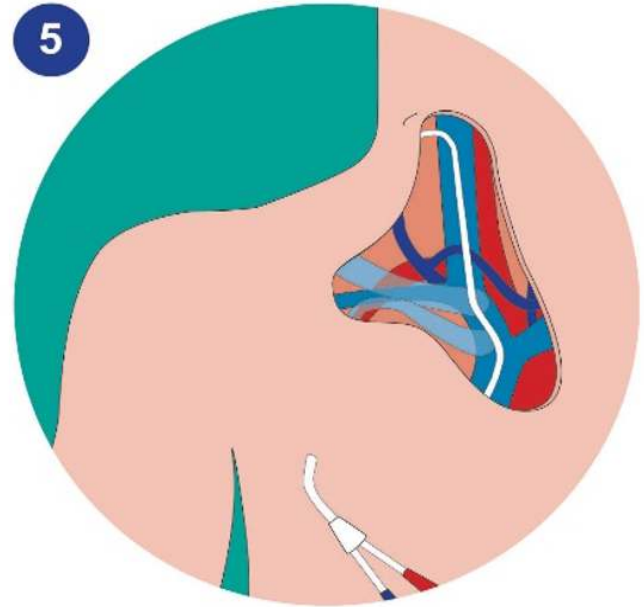
- The catheter should then be fed into the sheath
- The sheath is peeled away, leaving the catheter in the SVC / RA.



Catheter fed through peel away sheath.  
Sheath peeled away.

# Finally

- Pull downwards on the catheter from the exit site then straighten out
- Use steristrips, engineered securement device or skin glue to close exit and entry sites
- Flush and dress with a clear, breathable dressing
- Chest x-ray to check final tip position
- Document & Educate: staff and patient.

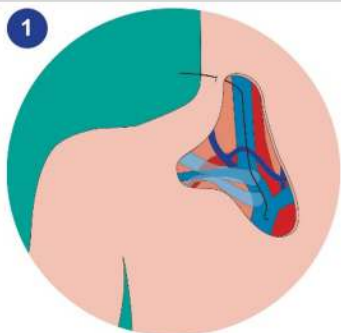


Final catheter position.

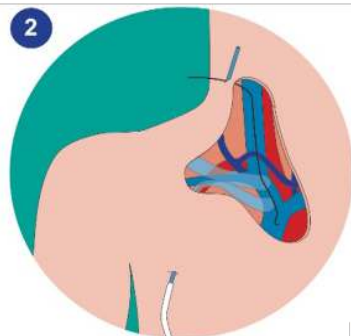


# Procedure

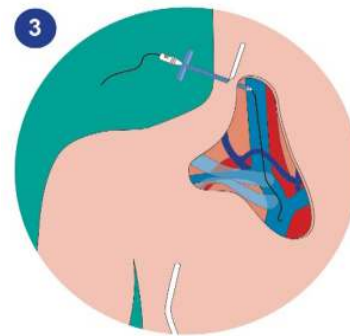
## Step-by-step guide



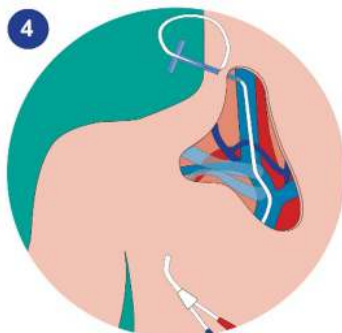
1 Puncture to jugular vein using 19g needle, wire introduced.



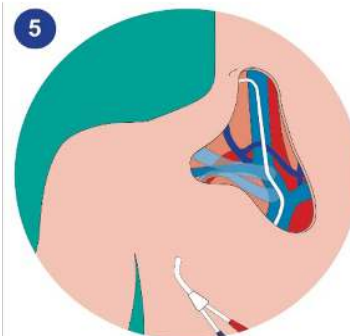
2 Tunnel fashioned back to point of entry.



3 Peel away sheath advanced over wire.

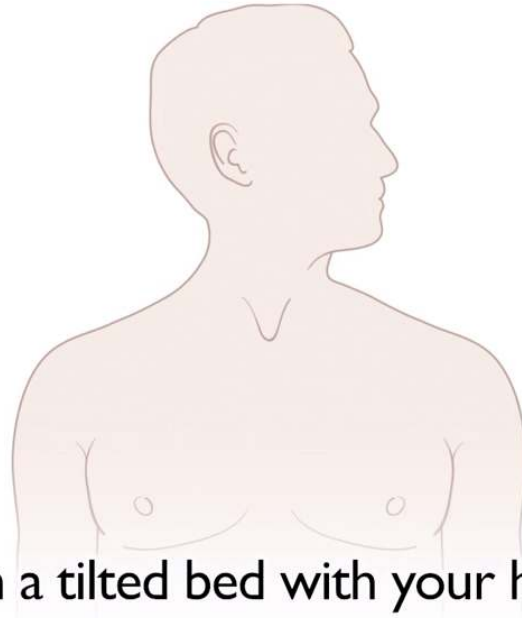


4 Catheter fed through peel away sheath.  
Sheath peeled away.



5 Final catheter position.

# Procedure



You lie on a tilted bed with your head turned to the left and lower than your feet

# TCVC

## Insertion complications

- Arterial puncture
- Pneumothorax
- Haemothorax
- Air embolism
- Failure to place

# TCVC

## Late complications

- Infection – local, systemic, tunnel
- Occlusion – thrombotic, mechanical
- Inadvertent dislodgment (cuff visible)
- Fracture – repair possible.

# TCVC

## Care & maintenance

- Observe the access site and exit regularly
- Remove exit site suture after three weeks
- If dressing required, change every seven days or sooner if loose or soiled
- Change needle-free device every seven days or as per manufacturers guidelines
- Biopatch (if used) is changed every seven days.

# TCVC

## Training material

- Insertion competencies
- Care and Maintenance competencies
- Care and Maintenance presentation
- Patient Information leaflets
- Video animation (to come)
- Chester Chest
- Potential for visits and training in NHSGGC.



**Any questions?**